

CASE STUDIES

TNF-alpha blockade may improve autonomic dysfunction in ankylosing spondylitis

Inderjeet Verma¹, Pawan Krishan¹, Ashit Syngle^{2*}

¹Department of Pharmaceutical Sciences & Drug Research, Punjabi University, Patiala, India

²Director Cardio Rheuma & Healing Touch City Clinic, Chandigarh & Senior Consultant Physician & Rheumatologist Fortis Multi Speciality Hospital, Mohali, India.

Abstract

The incidence of autonomic neuropathy in ankylosing spondylitis (AS) is well recognized. However, there are no studies demonstrating the therapeutic efficacy of TNF-alpha blockade in autonomic dysfunction of AS. We report here a case of a 36-year-old male of AS with high disease activity and autonomic symptoms, investigated for autonomic neuropathy. Non-invasive tests based on peripheral and cardiovascular autonomic neuropathy function were used for accurate assessment of autonomic neuropathy. The patient was treated with intravenous infusion of infliximab 5 mg/kg at weeks 0, 2, and 6. The 6 weeks therapy improved the disease activity, biomarkers of inflammation, and autonomic function. To the best of our knowledge, this is the first reported case of improvement in autonomic function associated with AS.

Introduction

Autonomic neuropathy is a significant risk predictor of sudden cardiac death in rheumatic disorders.¹ However, there is no specific treatment for autonomic neuropathy in rheumatic disease. Treatment with TNF-inhibitors (TNFi) has revolutionized the treatment of ankylosing spondylitis (AS). Their beneficial effects on musculoskeletal inflammation and endothelial dysfunction have also been reported.² The present case study describes the improvement of autonomic neuropathy with infliximab in AS.

Case report

A 36-year-old male patient diagnosed with AS around 2.6 years ago, presented with sacroiliac joint irregularity and marrow edema parallel to the joint (Figure 1). He was treated with TNFi-infliximab 5 mg/kg/dose as intravenous infusion at weeks 0, 2, and 6 along with sulfasalazine 500 mg thrice/day and etoricoxib 90 mg/day. In addition to inflammatory low back pain and joint pain, the patient complained about light headedness, and impaired sweating and bloating after eating a small meal. These symptoms were suggestive of autonomic dysfunction. High erythrocyte sedimentation rate (ESR) of 29 mm/1st hr, and high c-reactive protein (CRP) of 11mg/dl were noted. MRI of sacroiliac joints is depicted in figure 1. Bath Ankylosing Spondylitis Disease Activity Index (BASDAI) and Bath

Ankylosing Spondylitis functional Index (BASFI) were also high (Table 1). The patient was normotensive and non-diabetic with high disease activity. Results of routine hematological and biochemical investigations were within the normal limits. He was also investigated for autonomic neuropathy before starting the therapy. Cardiovascular autonomic neuropathy (CAN) function was evaluated by conducting cardiovascular reflex tests (Table 1) according to Ewing and peripheral sympathetic autonomic function by FDA-approved Sudoscan (Sudoscan-Impeto Medical Device, EZS 01750010193, Paris- France).^{3,4}

Results and Discussion

The patient was diagnosed with HLA-B27+ve AS around 2.6 years ago. He was normotensive and non-diabetic with a history of synthetic disease modifying anti-rheumatic drug (DMARD) failure. The patient showed remarkable improvement in disease activity and biomarkers of inflammation (ESR and CRP) as well as parasympathetic, sympathetic, and peripheral sympathetic autonomic dysfunction in 2 weeks, and normalization of autonomic dysfunction after 6 weeks of treatment with infliximab (Table 1). Autonomic symptoms were also ameliorated after treatment with infliximab. Autonomic dysfunction, a condition first described by Toussirot in 1999 in AS patients, is well documented in literature.⁵⁻⁹ The prevalence of autonomic neuropathy has been reported to vary from 24-

Figure 1: Sacroiliitis of ankylosing spondylitis. MRI (axial T1W and STIR) images of the HLA B27 +ve patient with inflammatory back pain showing sacroiliac joint irregularity and marrow edema parallel to the joint

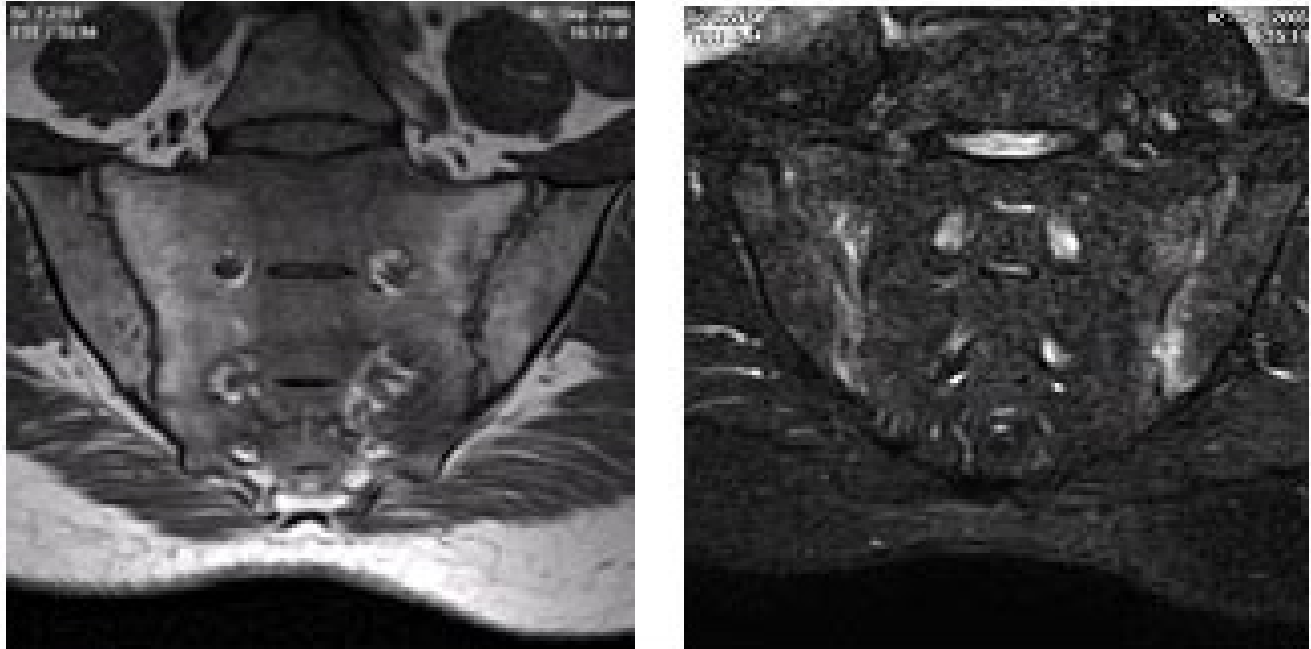


Table 1: Results of autonomic profile and clinical tests

Normal parameters value	Normal range	0 week	2 weeks	6 weeks
HR response to valsalva (PS)	≥ 1.21	1.28	1.27	1.29
HR response to deep breath (PS)	≥ 15	08*	13	19
HR response to standing (PS)	≥ 1.04	1.0*	1.07	1.08
BP response to standing (S)	SBP ≤ 10	07	6	6
BP response to handgrip (S)	DBB ≥ 16	06*	10	18
Sudoscan (S)	$> 60 \mu s$	56*	83	87
ESR mm/1st hr	0-10	29	10	09
CRP mg/dl	< 6	11	6.90	6
BASDAI	< 2.6	6.4	4.3	2.8
BASFI	---	3.2	3.3	3.0

PS: parasympathetic damage; S: sympathetic damage; HR: heart rate; SBP: systolic blood pressure; DBP: diastolic blood pressure; ESR: erythrocyte sedimentation rate, CRP: C-reactive protein, BASDAI: bath ankylosing spondylitis disease activity index; BASFI: bath ankylosing spondylitis functional index . *Indicates autonomic dysfunction.

100% of patients with autoimmune rheumatic diseases.⁶ Despite its massive prevalence, the pathogenesis of the autonomic neuropathy in rheumatic diseases is not clearly understood.⁶ There is also no known therapeutic strategy for the management of autonomic neuropathy in rheumatic disease. However, CAN is a significant risk predictor for sudden cardiac death in rheumatic patients. Hence, a precise treatment for this comorbidity is imperative.

In the present case study, the treatment using infliximab has significantly reduced the high disease activity, inflammation and abnormal cardiovascular autonomic neuropathy, and peripheral sympathetic dysfunction. Hence it can be concluded that infliximab treatment may improve cardiovascular autonomic neuropathy and peripheral sympathetic dysfunction in AS.

The improvement of autonomic dysfunction by TNF-alpha therapy could be explained by the following theoretical evidence: Primarily, it has been reported that the inflammatory process itself might cause some autonomic abnormalities in AS patients.⁵ Secondly, the patients with raised ESR and increased CRP and high BASDAI score also have disturbances in the balance of the autonomic nervous system.⁵ Finally, there is numerous evidence for the contribution of the nervous system to inflammation.⁵

Conclusion

To the best of our knowledge this is first reported observation of improvement in autonomic neuropathy with infliximab, in AS. In conclusion, the present case highlights two important findings. First, abnormal cardiovascular autonomic function and peripheral sympathetic neuropathy appeared to be rapidly improved after treatment with infliximab. Second, TNF- α blockade does not appear to be the cause of autonomic neuropathy. Further studies are warranted to confirm these observations and explore the role of infliximab and other therapeutic molecules on autonomic neuropathy in AS.

Competing interests

The authors declare that they have no competing interests.

Acknowledgements

We are very thankful to UGC, New Delhi, India for supporting the research [No. F.10-1/2008(SA-I)].

Citation

Verma I, Krishan P, Syngle A. TNF-alpha blockade may improve autonomic dysfunction in ankylosing spondylitis. *IJRCL*. 2014;2(1):CS4.

Received: 14 June 2014, **Accepted:** 18 September 2014 **Published:** 29 September 2014

*Correspondence: Dr. Ashit Syngle, Healing Touch City Clinic, House No. 547, Sector 16-D, Chandigarh 160015, India
ashitsyngle@yahoo.com

References

1. Milovanović B, Stojanović L, Milićević N, Vasić K, Bjelaković B, Krotin M. Cardiac autonomic dysfunction in patients with systemic lupus, rheumatoid arthritis and sudden death risk. *Srp Arh Celok Lek*. 2010 Feb;138(1-2):26–32.
2. Syngle A, Vohra K, Sharma A, Kaur L. Endothelial dysfunction in ankylosing spondylitis improves after tumor necrosis factor- α blockade. *Clin Rheumatol* 2010; 29:763-70.
3. Ewing DJ, Clarke BF. Autonomic neuropathy: its diagnosis and prognosis. *Clin Endocrinol Metab* 1986; 15:855-88.
4. Mayaudon H, Miloche PO, Bauduceau B. A new method for assessing sudomotor function: relevance in type 2 diabetes. *Diabetes Metab* 2010; 36:450-4.
5. Toussiroit E, Bahjaoui-Bouhaddi M, Poncet J, Cappelle S, Henriot M, Wendling D, et al. Abnormal autonomic cardiovascular control in ankylosing spondylitis. *Ann Rheum Dis*. 1999 Aug;58(8):481–7
6. Stojanovich J. Autonomic dysfunction in autoimmune rheumatic disease. *Autoimmun Rev*. 2009; 8:569–72.
7. Kaya EB, Okutucu S, Aksoy H, Karakulak UN, Tulumen E, Ozdemir O, et al. Evaluation of cardiac autonomic functions in patients with ankylosing spondylitis via heart rate recovery and heart rate variability. *Clin Res Cardiol*. 2010 Dec;99(12):803–8.
8. Onrat E, Demirdal S, Dursun H, Çakır T, Kilit C, Aşşar A et al. A New cardiac autonomic function predictor (Heart Rate Turbulence) in patients with ankylosing spondylitis. *Turk J Rheumatol* 2010; 25:196-200.
9. Syngle A, Verma I, Krishan P, Garg N. Autonomic neuropathy in rheumatoid arthritis and ankylosing spondylitis: Peripheral sympathetic and cardiovascular autonomic function assessment. *IJRD* 2012; 15(Suppl. 1):85-87.