

## CASE STUDIES

# Bilateral involvement of dactylolysis spontanea (Ainhum) in a 62-year-old female

Reena K Sharma<sup>1</sup>, Mudita Gupta<sup>2\*</sup>, Saru Thakur<sup>3</sup>, Smriti Sood<sup>4</sup>

<sup>1-4</sup>Department Of Dermatology, Venereology and Leprosy, Indira Gandhi Medical College, Shimla, Himachal Pradesh, India

### Abstract

Ainhum, also known as 'dactylolysis spontanea', is a rare condition of unknown etiology. It involves the formation of a groove or fissure of constricting band around the proximal end of the 5<sup>th</sup> toe. The groove deepens with the passage of time leading to auto-amputation. The present study discusses the case of a 62-year-old female with bilateral ainhum of the fifth toe.

Keywords: dactylolysis spontanea, bilateral ainhum, Z plasty

### Introduction

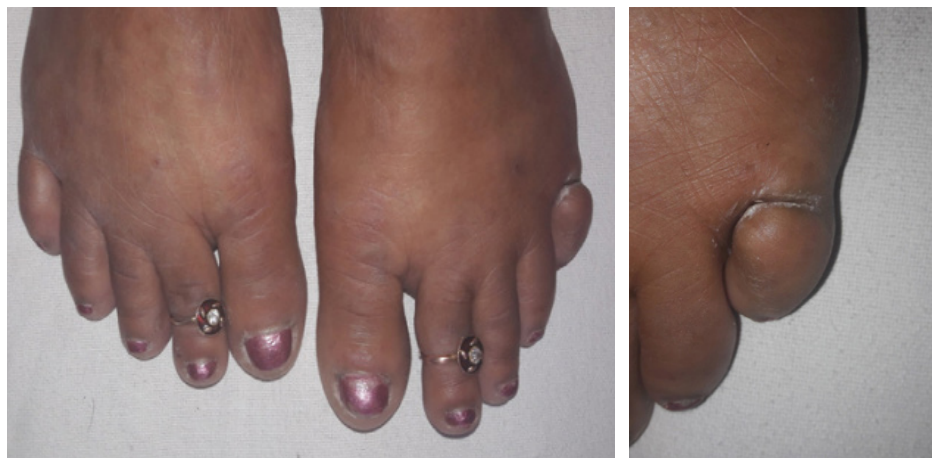The term 'ainhum', first used by da Silva Lima in 1867 from Bahia, Brazil, is derived from ayun meaning 'saw' in the language of Lago tribe of Nigeria and 'fissure' in the language of Brazilian Nago tribe.<sup>1</sup> It typically affects both little toes; but in rare cases, other toes and even fingers may be involved.<sup>2</sup> Pain of variable intensity is a common feature. Both sexes are affected, but it is more common in men. The present study discusses a case diagnosed with ainhum, an under-reported entity in literature.

### Case report

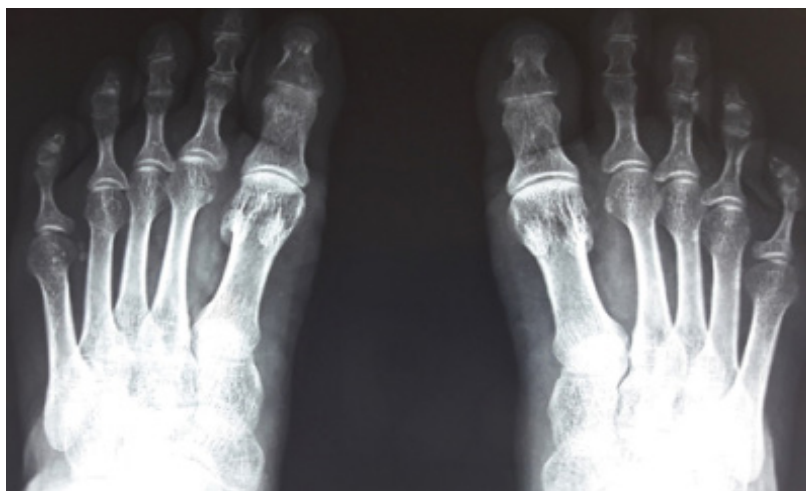
A 62-year-old female presented with slowly progressive painful constriction of fifth toe in the left leg for the past 10 years.

The patient was experiencing a feeling of tightness and pain for the last 1 year, which aggravated for the past 15 days. There was no relation of pain to walking distance, but it increased on movement of digits. She was a villager from a hilly area and the practice of walking barefoot is common in this part of country. There was no history of obvious trauma, ulceration, gangrene, sensory loss, plantar keratoderma or any or any other neurovascular systemic diseases. She was a non-smoker and non-alcoholic. There was no family history of similar complaints. Physical examination had noted a circumferential constriction over the proximal metatarsophalangeal joint of both 5<sup>th</sup> toes with distal bulbous swelling (Fig.1). Constriction band on left side was deeper than right side leading to 50%

**Fig 1: Bilateral grooving of fifth toe at the level of metatarsophalangeal joint and distal bulbous swelling (more prominent over left side)**



**Fig 2: Radiography showing constriction of soft tissue and thinning of underlying bones**



detachment, clawing and outward rotation of distal part of toe. Peripheral pulses were bilaterally normal. There was no sensory or motor weakness. There was no plantar keratoderma. Routine hematological and biochemical tests were normal. Antinuclear antibody test was negative. X-ray of the foot showed constriction of soft tissue over the metatarsophalangeal joint with thinning of underlying bones (Fig. 2). After clinical and radiological examinations, the diagnosis was concluded as bilateral ainhum stage II. She was advised amputation of left fifth toe and Z plasty surgery for right one.

### **Discussion**

The constricting bands around the digits can be idiopathic (ainhum) or secondary to other diseases (pseudoainhum). Ainhum is most common among native Africans and it may also occur in other races. Higher incidence of ainhum (0.015% to 2%) was noted in tropical and subtropical areas.<sup>3</sup> Commonly affected age group is between 20 and 50 years, and increased male preponderance has been noted (2:1).<sup>3</sup> According to Dent *et al.*, the condition is thought to be due to an abnormal blood supply to the foot, with the attenuation of posterior tibial artery at the ankle resulting in defective healing at trauma site.<sup>2</sup> In the present case, there was no evidence of vascular insufficiency, peripheral pulses and increase in temperature. Mechanical factors, including trauma from walking barefoot, may increase the risk of developing a groove in the ischemic toe. However, the exact cause remains unknown.<sup>2</sup> The increased prevalence of the disease in certain ethnic groups and families highlights the importance of genetics in the causation of ainhum.<sup>2</sup> A thick fibrotic band develops from a flexural groove and progressively constricts the

full circumference of the toe until its resolution through spontaneous amputation. Persistence of pain could be due to ischemia, nerve compression or osteolysis.

Ainhum has to be differentiated from pseudoainhum, which occurs secondary to some hereditary or non-hereditary diseases that lead to annular constriction of digits. Pseudoainhum can be associated with disorders of keratinization, syringomyelia, diabetes mellitus, infection (syphilis, leprosy), trauma (burn, frostbite), and connective tissue diseases (localized scleroderma, systemic sclerosis, discoid lupus erythematosus).<sup>4</sup> Constriction of amniotic band may also lead to pseudoainhum noted in childhood. Pseudoainhum may involve multiple digits and have features of the underlying disease.

Criteria for diagnosis involve any one of the three conditions: soft tissue constriction, bulbous enlargement of the toes, and thinning or lysis of phalangeal bones. Cole has described the following four clinical stages of ainhum:<sup>5</sup>

- First stage: A small clavus or callus develops, which progresses to a narrow groove or fissure encircling the toe
- Second stage: The toe becomes globular distal to the groove, associated with arterial narrowing and bone resorption
- Third stage: Very painful; the bone separates at the joint with hypermotility of the toe
- Fourth stage: Characterized by a bloodless autoamputation of the toe.

Early diagnosis and treatment can help prevent progression

of ainhum to mutilating deformities. Early cases of ainhum may respond to intralesional steroids, salicylate preparations, retinoids and conservative plastic repair with a Z-plasty or similar relaxing closure that prevents further disease progression and damage to underlying structures. Amputation is required to relieve pain and prevent infection in stage III and IV.<sup>6</sup> In the current case, the left toe had stage II ainhum, amputation was planned because of extreme pain and increased detachment while right one was planned for Z plasty.

Although ainhum may appear as not so serious, it is a very troublesome condition and should be treated according to the stage and symptoms.

#### Competing interests

The authors declare that they have no competing interests.

#### Citation

Sharma RK, Gupta M, Thakur S, Sood S. Bilateral involvement of dactylolysis spontanea (Ainhum) in a 62-year-old female. *IJRCI*. 2018;4(1):CS6.

**Submitted:** 6 June 2018, **Accepted:** 23 November 2018, **Published:** 30 November 2018

\*Correspondence: Dr. Mudita Gupta, Assistant Professor, Department Of Dermatology, Venereology and Leprosy, Indira Gandhi Medical College Shimla, Himachal Pradesh, India  
muditadrguptayahoo.com

#### References

1. da Silva, Lima JF. On ainhum. *Arch Dermatol* 1880;6:367.
2. Priya BT, Suganthy RR, Manimegalai M, Krishnaveni A. Familial ainhum: A case report of multiple toe involvement in a father and son, staging of ainhum with insight into different types of constricting bands. *Indian J Dermatol* 2015;60:106.
3. Jemmott T, Foster AV, Edmonds ME. An unusual cause of ulceration: ainhum (Dactylolysis Spontanea). *Int Wound J* 2007;4:251-4.
4. González LF, González CA, Motta A, Rodríguez F. Ainhum (Dactylolysis Spontanea): A Rare Cause of Consult in Dermatology- A Case Report and Review of Literature. *Austin J Dermatol* 2017;4:1068.
5. Cole GJ. Ainhum: An account of fifty-four patients with special reference to etiology and treatment. *J Bone Joint Surg Br* 1965;47:43-51.
6. Prabhu R, Kannan NS, Vinoth S, Praveen CB. Ainhum - A Rare Case Report. *J Clin Diagn Res* 2016;10:17-18.