

CLINICAL CASE VIGNETTES

Recurrent painful panniculitis: Erythema induratum

Sham Santhanam^{1*}, Susie Samuel²

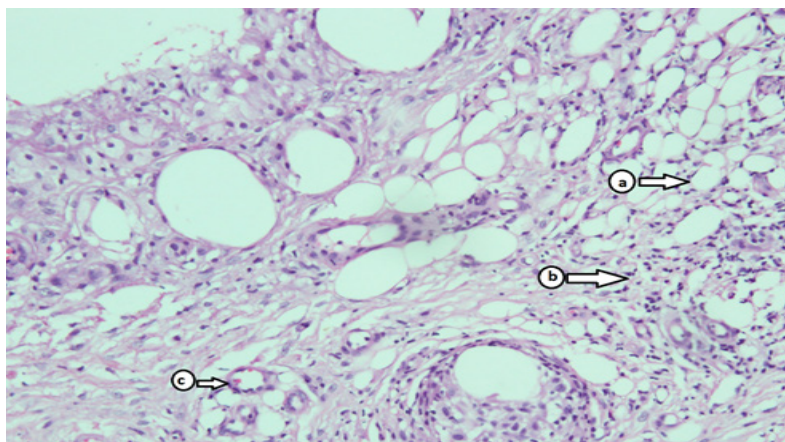
^{1,2} Global Hospitals, Chennai, India

Erythema induratum is the presentation of mixed septal and lobular granulomatous panniculitis, with or without vasculitis. It usually affects females in their 3rd to 4th decade and has a predilection for calf muscle area. The disease appears as recurrent, painful, refractory lesions, which may (Bazin's type) or may not be (Whitfield's type) associated with tuberculosis. The figure 1 shows the development of painful nodules with ulceration on the posterior aspect of leg (calf muscle region) in a 32-year-old lactating female. Findings of skin biopsy (Fig.2) were also consistent for erythema induratum (nodular vasculitis). Additional workup did not indicate any other conditions including latent tuberculosis.^{1,2}

Fig 1: Healed lesions on the posterior aspect of leg

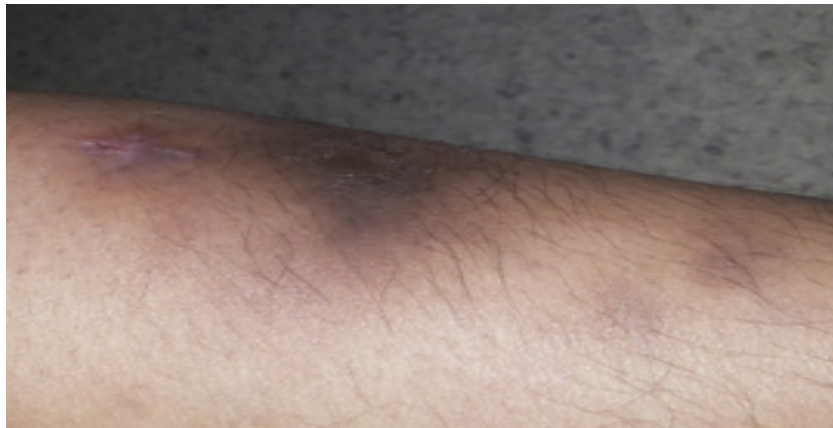

Fig 2: Skin biopsy (subcutaneous fat): a- Inflammation of fat lobules; b- Inflammation of septae; c- Inflammation of vessel walls



Competing interests

The authors declare that they have no competing interests.

Citation

Sham S, Susie S. Recurrent painful panniculitis: Erythema induratum. IJRCI. 2015;3(1):V3.

Received: 6 April 2015, **Accepted:** 7 April 2015, **Published:** 21 April 2015

* Correspondence: Dr.Sham S, Global Hospitals, Chennai, India
itsdrsham@gmail.com

References

1. Gilchrist H, Patterson JW. Erythema nodosum and erythema induratum (nodular vasculitis): diagnosis and management. *Dermatol Ther.* 2010 Jul-Aug;23(4):320-7
2. C. Nirmala and A.H. Nagarajappa. Erythema induratum - A type of cutaneous tuberculosis. *Indian J Tuberc* 2010; 57:160-164.